

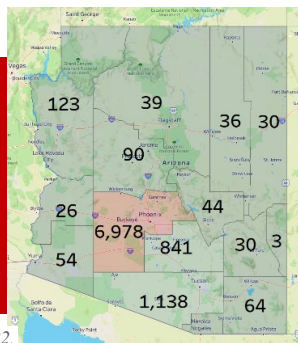
The Clinician's Guide to Diagnosing Primary Pulmonary Coccidioidomycosis in Arizona

WHAT IS COCCIDIOIDOMYCOSIS?

Coccidioidomycosis, commonly known as **Valley fever**, is caused by the fungus **Coccidioides**. The fungus lives in the desert soil, and infection occurs after inhalation of airborne microscopic spores, called **arthroconidia**.

While infection may be associated after a history of dust or soil exposure, most infections occur without such events. Simply living in or traveling to the coccidioidal endemic region is a risk factor for acquiring coccidioidomycosis.

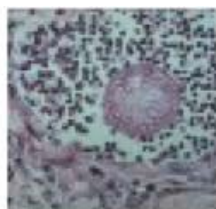
Valley fever is a frequent infection in Arizona, particularly in Maricopa, Pinal, and Pima counties, which include the metropolitan areas of Phoenix and Tucson, as well as Casa Grande and Florence.



Right: Number of Valley fever cases reported in Arizona in 2022.

Infection generally becomes apparent 7–28 days after inhalation of arthroconidia. Although infection may be acquired at any time of year, the peak seasons for coccidioidomycosis in Arizona are the early summer and late fall.

When arthroconidia reach lung tissue, they initiate infection and change their morphology by rounding and septating. Such structures are called **spherules**. The response to infection is to encase spherules within granulomata to control fungal growth. However, the fungus is not killed by this process.

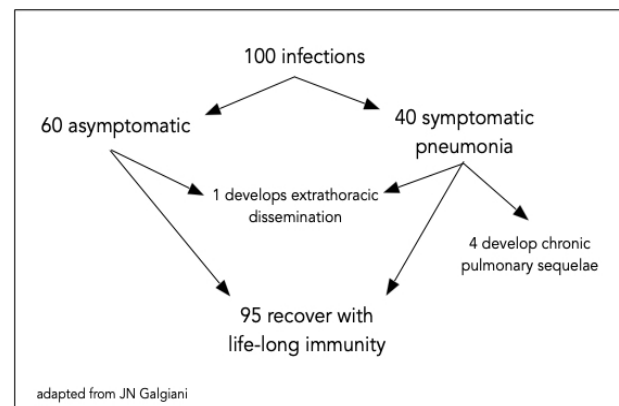


Spherule surrounded by lymphocytes from tissue biopsy

A biopsy of a coccidioidal lung lesion will demonstrate the **spherule** surrounded by the granuloma, and this is diagnostic of infection.

WHAT ARE THE OUTCOMES OF COCCIDIOIDOMYCOSIS INFECTION?

The diagram below shows the possible outcomes of coccidioidomycosis infection using an example of 100 infections:



- **60%** of those who become infected are **without symptoms**.
- **40%** develop a **pneumonia syndrome** that may be **indistinguishable from a bacterial community-acquired pneumonia (CAP)**.
- **5%** of all infected patients have **complicated courses**, either because of persistent pulmonary disease, or because of the development of infection outside the thoracic cavity, called extrathoracic dissemination.

- ➔ **It is estimated that about 20% (1 in 5) of all pneumonias in Arizona are due to coccidioidomycosis.**
- ➔ **Therefore, it is imperative that any patient who develops an acute pneumonia while living in or traveling to Arizona be tested for coccidioidomycosis.**

RECOGNIZING PRIMARY PULMONARY COCCIDIOIDOMYCOSIS

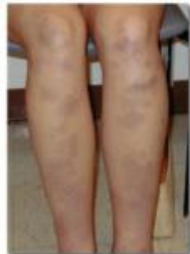Symptoms

- In addition to chest pain and cough, persons with pulmonary coccidioidomycosis frequently complain of **night sweats**, which are often drenching and a major component of the illness.
- Fever with chills is less frequent in coccidioidomycosis compared to bacterial causes.
- The patient may present with a **dull headache, weight loss**, and marked **fatigue**, symptoms that are uncommon in bacterial CAP.
- A **failure to improve** after one or more courses of bacterial antibiotics or persistence of symptoms over weeks is strongly suggestive of coccidioidomycosis.

Clinical Signs

Patients with primary pulmonary coccidioidomycosis frequently present with a **rash**.

- The rash may be **erythema nodosum**, consisting of hard, red, painful nodules usually on the lower extremities. Erythema nodosum in Arizona is associated with a very high rate of coccidioidal serologic positivity (see Pu J, et al OFID 2023).
- Another rash is **erythema multiforme**, a patchy, bull's eye rash often in necklace distribution; or a diffuse erythroderma, similar to a drug allergy.
- An inflammatory nodular eruption on the back or trunk that resembles Sweet's syndrome may be seen.
- Patients may present with painful, symmetric **arthralgias**, typically involving the ankles, knees, hips and elbows. Examination may reveal pain on movement. This has been called "desert rheumatism."

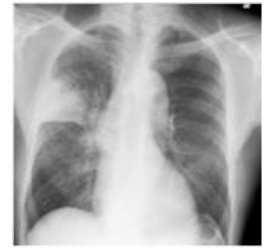


Erythema nodosum in primary pulmonary coccidioidomycosis

Laboratory findings

The radiographic findings of primary pulmonary coccidioidomycosis can be distinct.

- The pulmonary infiltrate is often **dense and rounded**.
- It frequently is located in the **upper lobe**, which is very unusual in bacterial CAP.
- There may be either **hilar or mediastinal adenopathy**.



Right upper lobe infiltrate during primary pulmonary coccidioidomycosis

If any of these findings are present, it is unlikely that this is bacterial CAP and more likely that coccidioidomycosis is the diagnosis.

Coccidioidomycosis may be confused with pulmonary tuberculosis (TB). Both present with cough, night sweats, and weight loss, with chest imaging revealing upper lobe processes with or without cavitation. If a patient presents with these findings, it is appropriate to test for TB and coccidioidomycosis. Note that a diagnosis of one does not exclude the other.

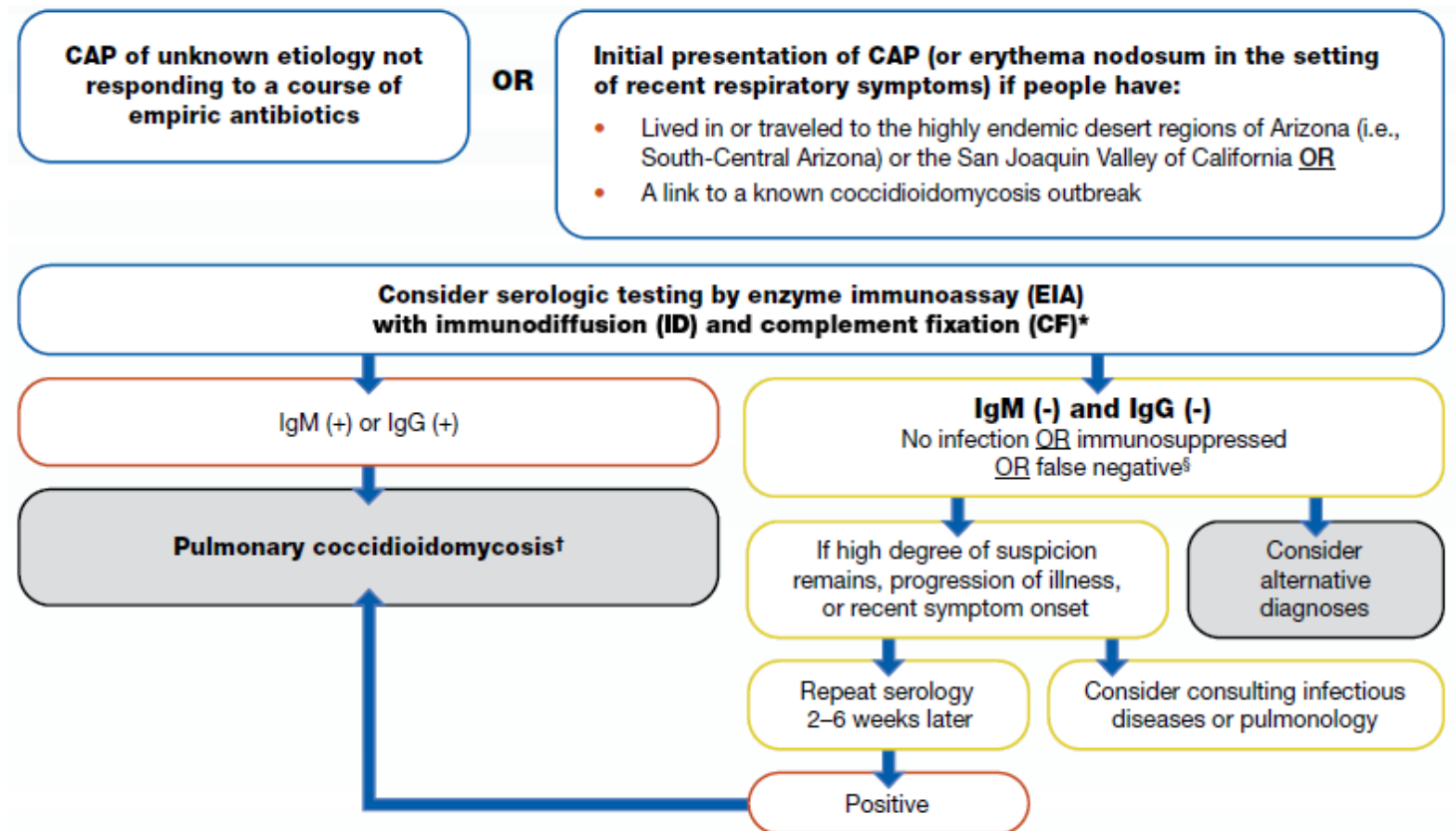
TESTING FOR PRIMARY PULMONARY COCCIDIOIDOMYCOSIS

Several tests are available, including the enzyme immunoassay (EIA), immunodiffusion (ID) and complement fixation (CF).

1. In Arizona, the enzyme immunoassay (EIA) for immunoglobulin M (IgM) and immunoglobulin G (IgG) is readily available and sensitive. If one or both of these EIA tests are positive in the context of a pulmonary infection with recent residence/travel to Arizona, then coccidioidomycosis should be considered as a diagnosis.
Note: A positive coccidioidal antibody, especially IgG, is generally a marker for **active infection** and does not indicate immunity or control of coccidioidal disease.
2. In such cases, **an ID and CF serology should be obtained next, to confirm the EIA results.**

The diagnosis of Valley fever can also be established by culturing *Coccidioides* from the sputum or other respiratory samples or by noting spherules in these samples, although these have low sensitivity.

A complete **serological testing algorithm** from the Centers for Disease Control (CDC), Mycoses Study Group (MSG), and Coccidioidomycosis Study Group (CSG) can be found below and online.



Above: Community-Acquired Pneumonia (CAP): Clinical Testing Algorithm for Coccidioidomycosis
<https://www.cdc.gov/fungal/diseases/coccidioidomycosis/diagnosticalgorithms/>

RESOURCES

1. [Valley Fever. A Training Manual for Primary Care Professionals](#) — Valley Fever Center for Excellence, University of Arizona
2. [2016 Infectious Diseases Society of America \(IDSA\) Clinical Practice Guideline for the Treatment of Coccidioidomycosis](#)
3. [Community-Acquired Pneumonia \(CAP\): Clinical Testing Algorithm for Coccidioidomycosis](#) — Centers for Disease Control and Prevention
4. [Primary pulmonary coccidioidal infection](#) — UpToDate